

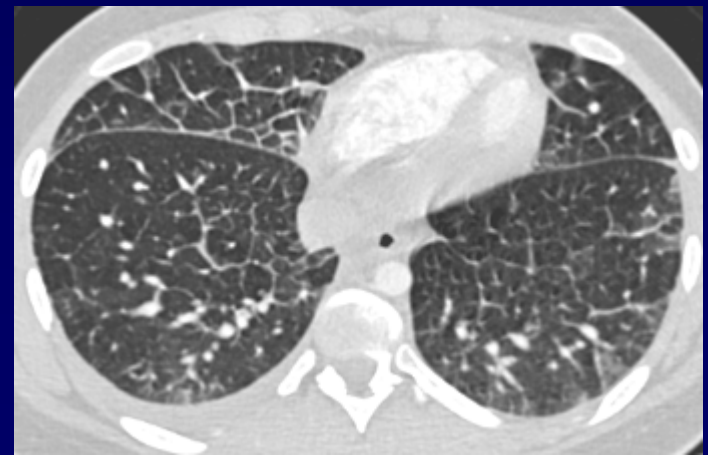
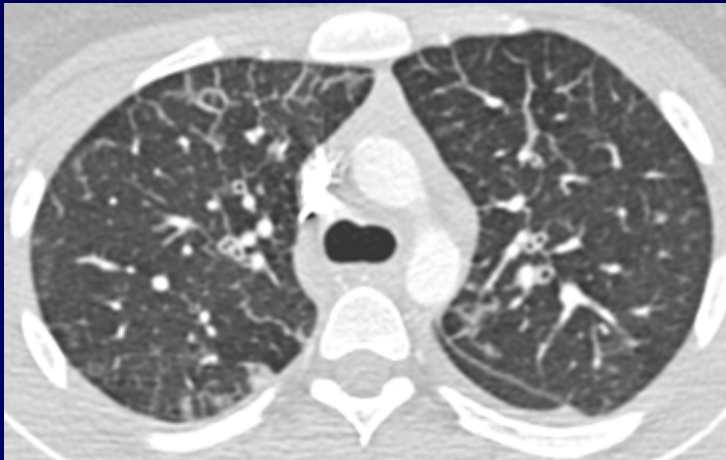
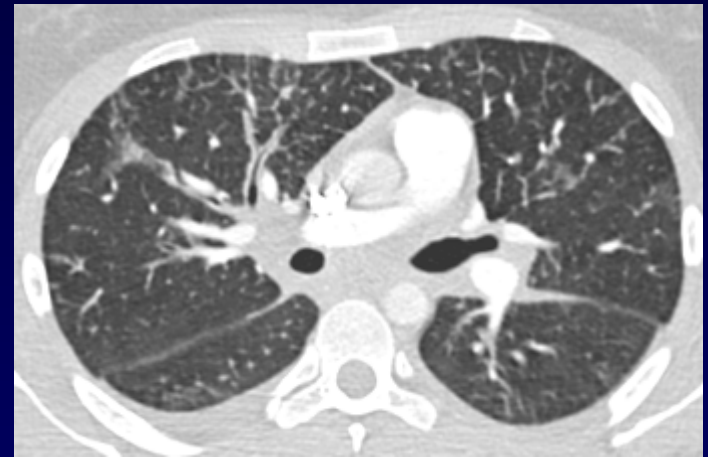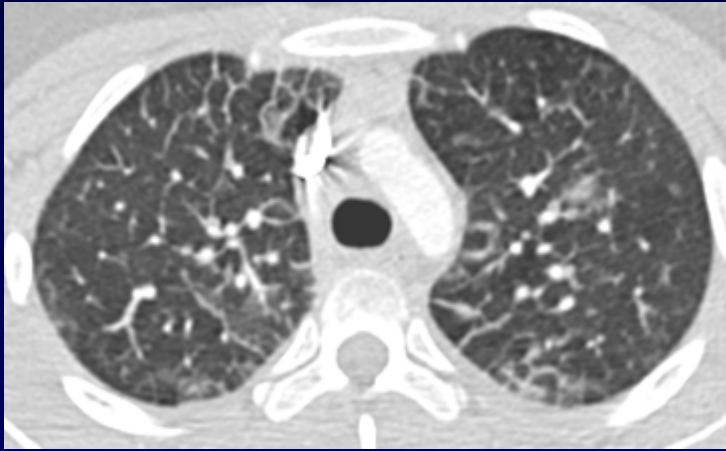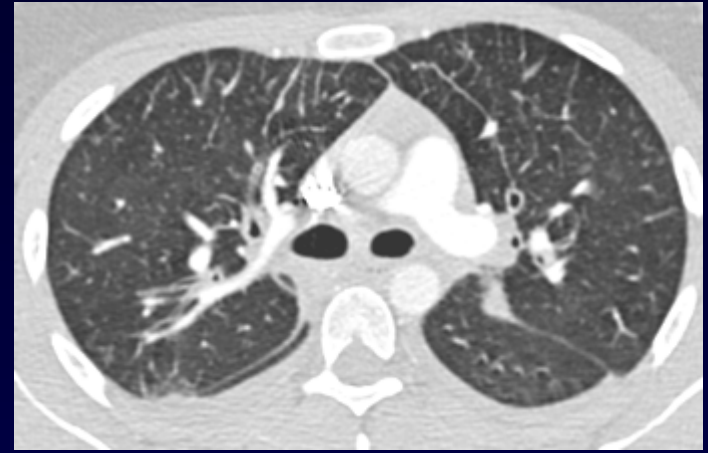
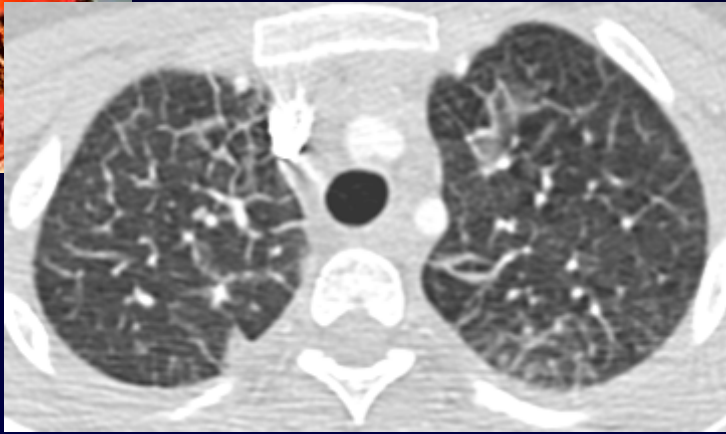


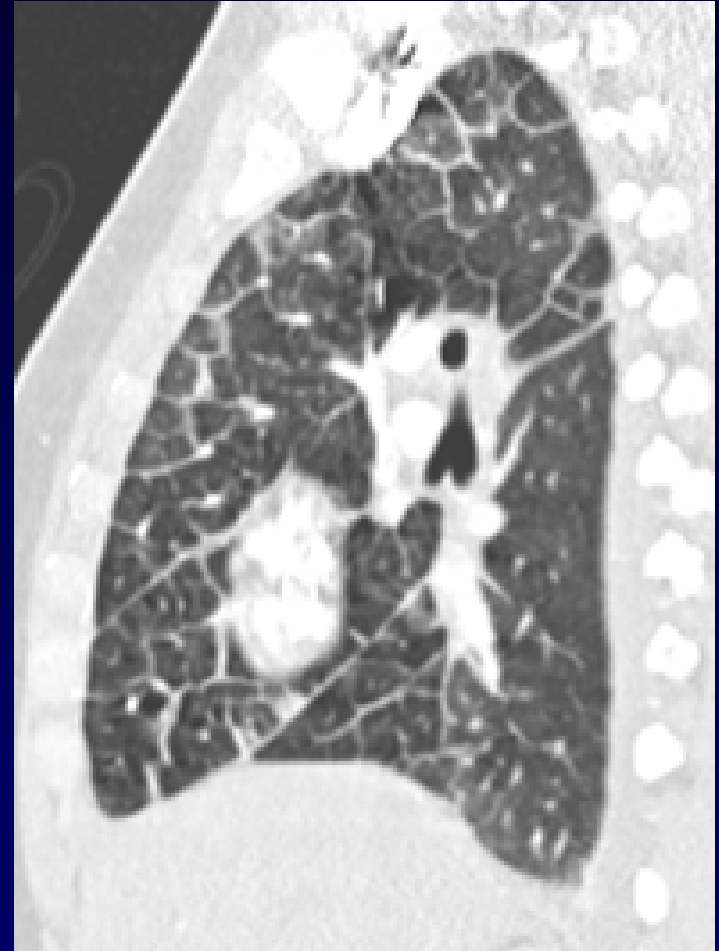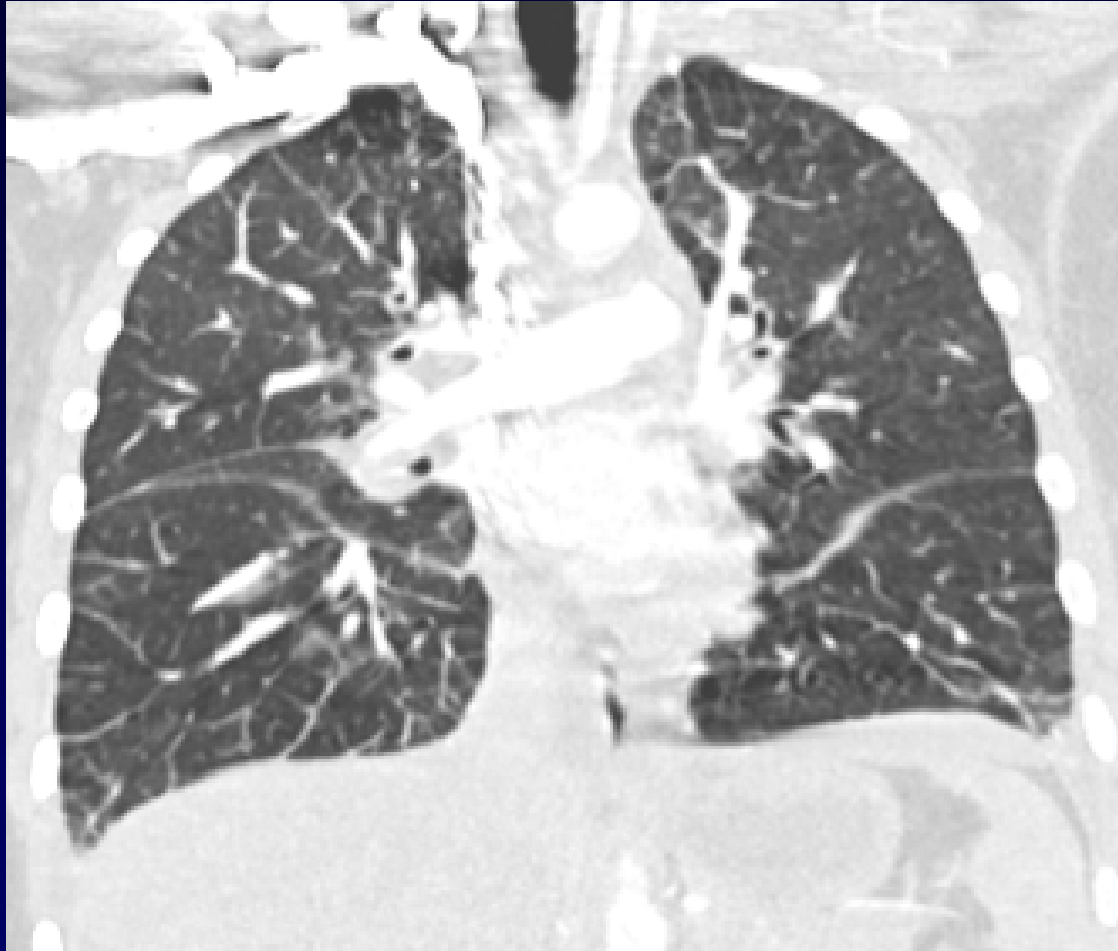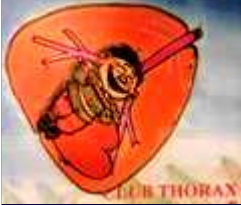## **Dossier 16**

**MP DEBRAY**

**Patiente de 40 ans**

**Dyspnée aigue fébrile**







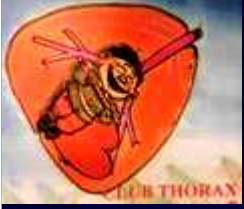**Diagnostic ?**



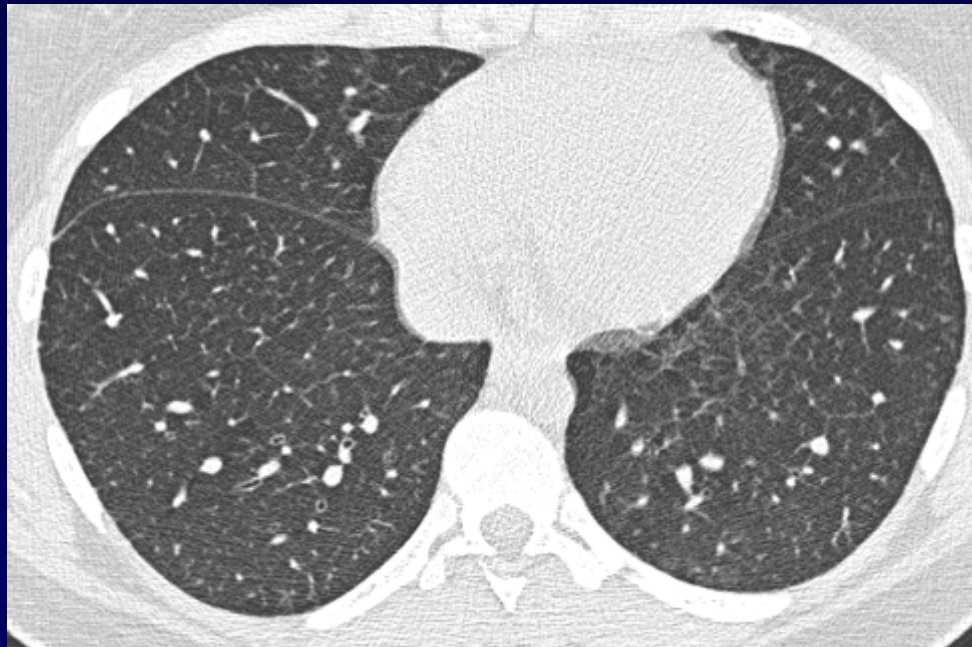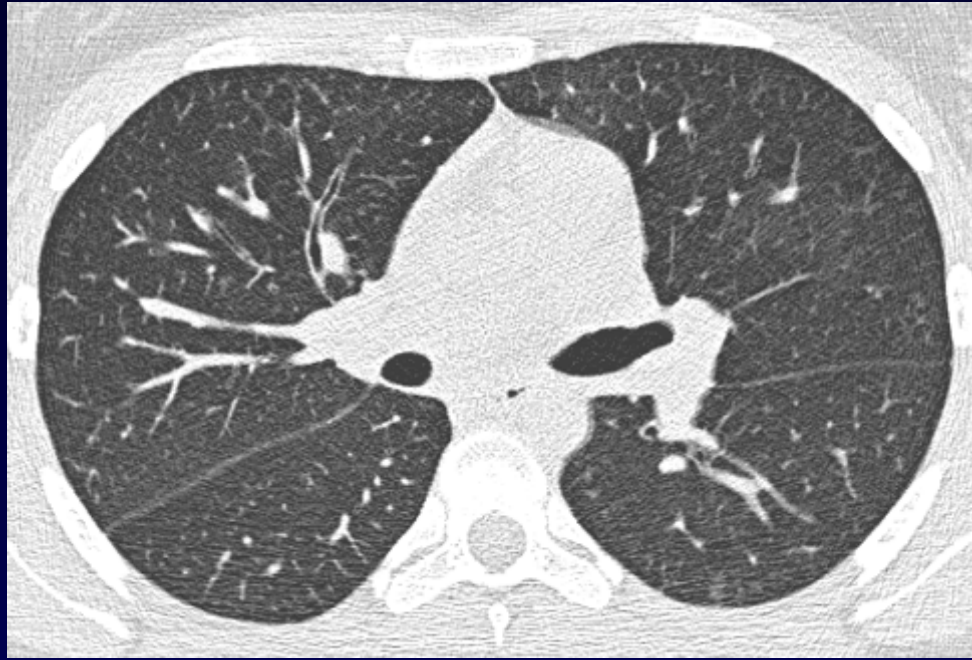
- **Echographie cardiaque : normale**
- **NFS : Hyperleucocytose à PNN**

**Mise sous antibiothérapie**

**Amélioration clinique franche à J1**



J4





**Fibroskopie bronchique avec LBA : 50% éosinophiles**

**Diagnostic ?**



## **Diagnostic**

# **Pneumopathie aiguë à éosinophiles**

**Codage : Poumon – Infectieux - Inflammatoire**